

Scar endometriosis following caesarean section: report of two cases.

Shreedevi S. Bobati, Vijay D. Dombale, B. H. Kerudi¹, N. Kuntoji², Deepa Masur

Department of Pathology, S Nijalingappa Medical College, Bagalkot.

¹Consultant Surgeon, Kerudi Hospital, Bagalkot.

²Department of OBG, S Nijalingappa Medical College, Bagalkot.

Abstract

Endometriosis continues to be a mysterious and fascinating pathological entity that can be characterized as a simple disease with complex etiology. Scar endometriosis is an infrequent type of extra pelvic endometriosis that is rather close together with obstetrical and gynaecological surgeries. It is always confused with other dermatological or surgical conditions and delays the diagnosis. We report two cases of abdominal wall endometriosis following caesarean section. The incidence, pathophysiology, course, diagnosis, treatment and prevention of this condition is reviewed.

Keywords: Caesarean section, endometriosis, scar endometrioma.

Introduction

Endometriosis was first described by Rokitansky in 1860 and was defined as the presence and proliferation of endometrium outside the uterine cavity, commonest site being pelvis [1]. Scar endometriosis is a term given to endometriosis occurring following obstetrical and gynaecological surgeries in a Caesarean section scar. Scar endometriosis also called as endometrioma is a well-circumscribed mass. Mid trimester abortion via hysterotomy is associated with the highest occurrence rates (1.08–2%). It can be located at skin, subcutaneous tissue, rectus muscle/sheath, intraperitoneal or in the uterine myometrium[1].

The incidence of abdominal scar endometriosis following hysterectomy and caesarean section are 1.08-2% and 0.03-0.4% .

Differential diagnosis includes hernias, lipomas, hematomas, abscesses, suture granulomas , sebaceous cysts, malignant tumours including desmoid tumours, sarcomas, lymphomas or primary malignancies of the skin and metastatic tumours[2].

Time interval between operation and presentation of scar endometriosis varies from 3 months to 10 years[3].

Scar endometriosis is rare and difficult to diagnose, often confused with other surgical conditions.

Address for Correspondence:

Dr. V. D. Dombale
Professor and HOD, Dept. of Pathology,
S. Nijalingappa Medical College,
Navanagar, Bagalkot-587102.
E-mail: drvijaydombale@gmail.com

Case history-1

A 44-year old lady complained of swelling in the caesarean section scar operated 10 years back. The swelling was gradually increasing in size and was associated with cyclical pain since one year. Ultrasound of the pelvis showed hypoechoic mass with internal echoes, suggestive of hematoma [Figure-1]. On clinical examination there was a hard, round mass with mild tenderness at the right lateral edge of the caesarean section scar. Excision of the mass was done and sent for HPR .

Grossly: Skin covered fibro-fatty tissue mass measuring 12x8x4cms, with overlying skin measuring 12x4cms. Cut Section: Grey white area measuring 5x4cms with infiltrative margins were seen [Figure-2].

Microscopically: Foci of endometrial glands and stroma were noted. Pearl stain was positive for hemosiderin laden macrophages[Figure-3].

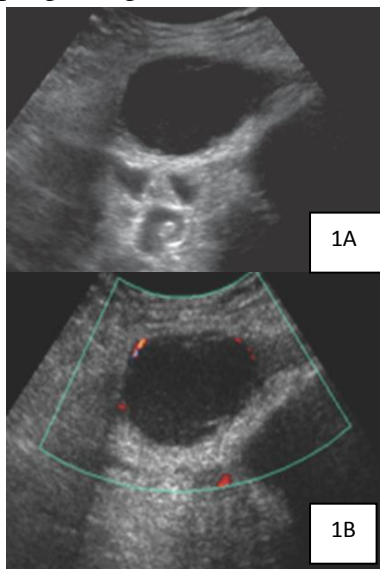


Figure 1. [A] Transabdominal pelvic USG image shows a hypoechoic mass with internal echoes in the left pelvic wall. [B] Color Doppler US image shows peripheral flow within the mass.

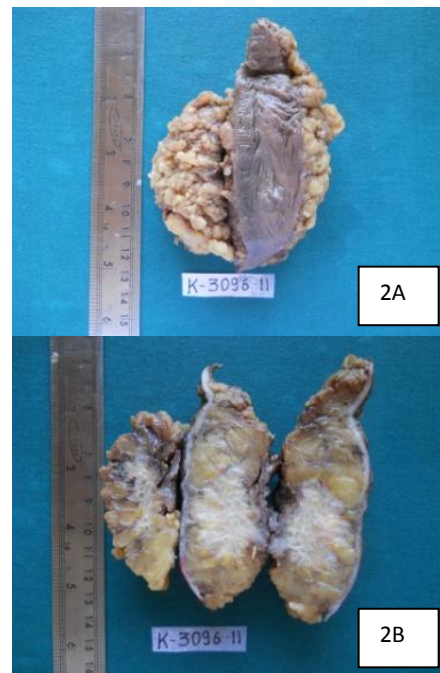


Figure 2. [A] Skin covered fibrofatty tissue measuring 12x8x4cms, overlying skin measuring 12x4cms. [B] C/S grey white area with infiltrative margins measuring 5x4cms.

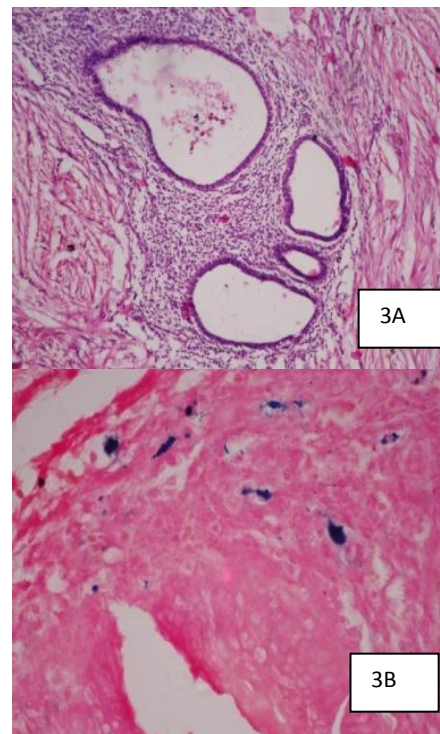


Figure 3. [A] Foci of endometrial glands and stroma. [B] Pearl stain positive for hemosiderin laden macrophages. [H&E 10X, 40X]

Case history-2

A 36-year old woman, underwent surgery for umbilical hernia nine months back and had also undergone caesarean section three years back . She complained of a painful swelling at the right margin of the surgical scar. On CT a slightly hyperattenuating soft-tissue nodule suggestive of desmoid tumour was diagnosed[Figure - 4]. FNAC suggestive of scar endometriosis. Excision of the mass was done and sent for HPR . Grossly: A skin covered globular soft mass measuring 14x13x5cms. Cut section: Gritty to cut and two irregular grey brown masses each measuring 3.3x2.2cms. Areas of calcification and haemorrhages noted [Figure-5].

Microscopically: Foci of endometrial glands and stroma surrounded by fibrous tissue of scar were seen[Figure-6].

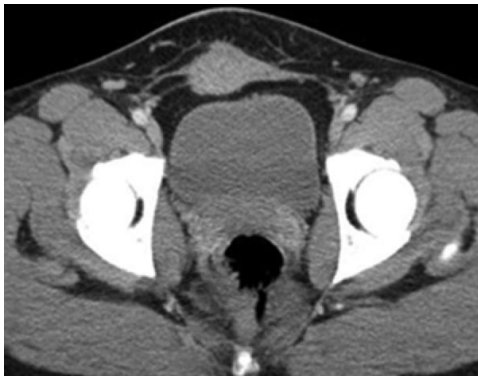

Figure 4. Contrast-enhanced CT image shows a slightly hyper attenuating soft-tissue nodule in the anterior pelvic wall along a prior surgical scar with infiltration of adjacent fat planes.

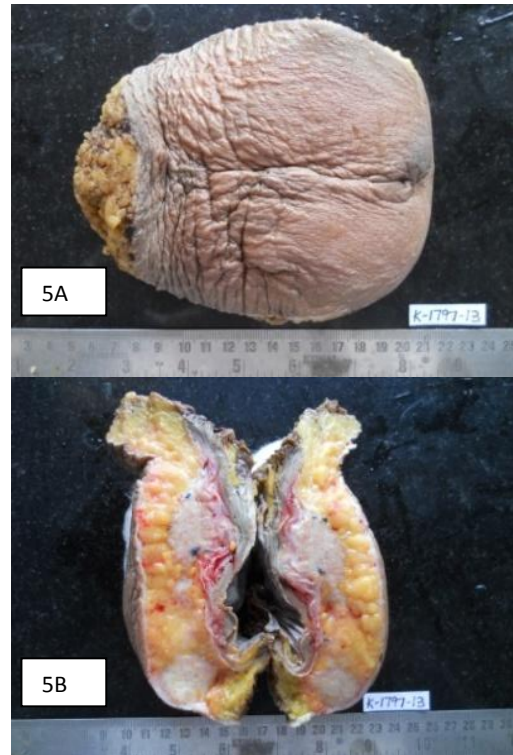


Figure 5. [A] Skin covered globular soft mass measuring 14x13x5cms. [B] C/S- Irregular two grey brown masses each measuring 3.3x2.2cms, with areas of calcification, gritty to cut. Areas of haemorrhages noted.

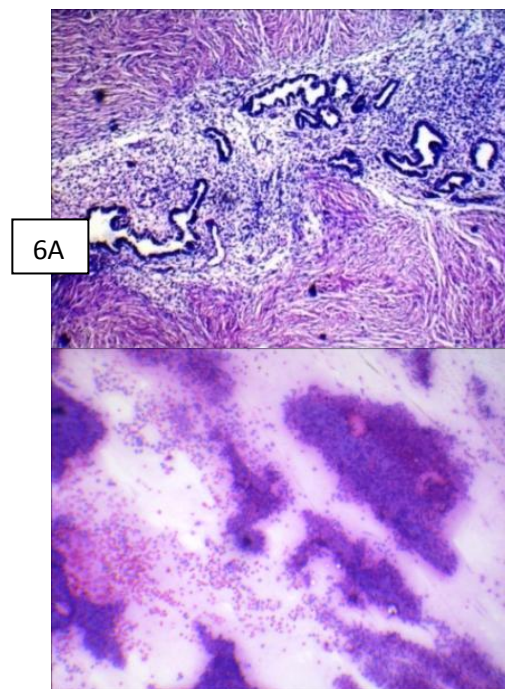


Figure 6. [A] Monolayered sheets of endometrial glandular cells with moderate cytoplasm and round to oval nuclei along with foci of spindle stromal cells. [B] Endometrial glands and stroma surrounded by fibrous tissue scar.

Discussion

The first case of scar endometriosis was reported by Meyer in 1903, with 1.6% of prevalence [4]. Scar endometriosis is common in women who have undergone caesarean section. The risk of this disease is seven times greater if a mother or sister had the disease [5]. But there are case reports of involvement of the rectus abdominis muscle in a virgin abdomen [6]. Several mechanisms can explain the incidence of scar endometriosis:

1. Direct implantation of endometrial cells at the time of the operation is the dominant explanation with subsequently stimulated by estrogen [2].
2. The lack of secure closure of the parietal and visceral peritoneum during caesarean section and reduced care to avoid dissemination of endometrial cells. This scenario, however, is rare and the increased incidence particularly after Caesarean section [0.03%] does not conform with this rate [2].
3. Metaplasia of peritoneal mesothelial cells which remain in the incision during the initial operation has also been reported [3].
4. The theories of lymphatic or vascular dissemination, as well as retrograde menstruation are not widely accepted [3].
5. Finally, the recent hypothesis that the presence of endometriosis is related to immunogenetic defects may explain its development *via* inadequate response of the peritoneal defensive system to the retrograde flow or implantation of endometrial tissue [3].

Scar endometriosis occurring in a subumbilical incision scar should be differentiated from umbilical endometriosis, also called Villar's Nodule, first described by Villarin 1886. Extremely

rare, the incidence being only 0.5-0.1% of all women with extra gonadal or external endometriosis[7].

On the contrary, review of the surgical literature indicates that preoperative diagnosis is often incorrect. Hence, whenever the diagnosis is uncertain, efforts should be made to make a preoperative diagnosis with the help of imaging techniques and FNAC. FNAC has been reported to be accurate in diagnosis but in a recent report by Dwivedi et al [8], this was not diagnostic in any of the four patients who underwent this procedure. Nonetheless it may be helpful in eliminating malignancy from the diagnosis. Caution should be used if suspicion of incisional hernia is present.

Malignant change of endometriosis in a caesarean scar is rare [9]. Long-standing recurrent scar endometriosis could undergo malignant changes and clinician should be aware. Clear-cell carcinoma is the most common histological subtype, followed by endometrioid carcinoma and carries a poor prognosis [10].

Conclusion

Endometriosis should be included in the differential diagnosis of lumps related to a surgical scar, inguinal canal and pelvis, especially if symptoms are cyclical. However, imaging techniques, laparoscopy and FNAC are indicated towards better diagnostic approach. Usually surgical excision is adequate management as in our cases, but selected cases require gynaecological referral and further medical therapy.

References

1. Azam A, Nahid A. Abdominal Incisional Endometriosis Following Caesarean Section: Report of 2 cases.

- Journal Of Family And Reproductive Health 2008;2 (2):107-10
2. Sinha R, Mohan K, Matah M. Abdominal scar endometriosis after Caesarean section: a rare entity. The Australasian Medical Journal 2011;4(1): 60-62.
 3. Thapa A, Kumar A , Gupta S. Abdominal Wall Endometriosis: Report Of A Case And How Much We Know About It?. The Internet Journal of Surgery 2007; 9(2). DOI: 10.5580/1690
 4. Agarwal N, Subramanian A. Endometriosis - Morphology, clinical presentations and molecular pathology. J Lab Physician 2010;2:1-9
 5. Lahiri AK, Sharma K, Busiri N. Endometriosis of the uterine cesarean section scar: A case report. Indian J Radiol Imaging 2008;18:66-8.
 6. Hashim H, Shami S. Abdominal Wall Endometriosis in General Surgery. The Internet Journal of Surgery 2002;3 (2)
 7. Michovitz M, Baratz M, Stavorovsky M. Endometriosis of the umbilicus. Dermatologica 1983;167: 326-30.
 8. Dwivedi AJ, Agarwal SN, Silva YJ. Abdominal wall endometriomas. Dig Dis Sci 2002;47:456-61.
 9. Sergent F, Baron M, Cornec JB et al. Malignant transformation of abdominal wall endometriosis: a new case report. J Gynecol Obstet Biol Reprod (Paris) 2006;35(2):186-90
 10. Leng J, Lang J, Guo L et al. Carcinosarcoma arising from atypical endometriosis in a cesarean section scar. Int J Gynecol Cancer 2006;16(1):432-5.

Conflict of interest: Nil

Source of funding: Nil